

Open abdomen in acute mesenteric ischemia

Stefan Acosta¹, Jussi Kärkkäinen²

¹Department of Clinical Sciences, Vascular Centre, Lund University, Malmö, Sweden

²Heart Center, Kuopio University Hospital, Kuopio, Finland

Abstract

In acute mesenteric ischemia, early diagnosis should optimally be followed by either open or endovascular intestinal revascularization. All too often, diagnosis is delayed and diagnosis and treatment are performed at the same time during explorative laparotomy. The majority of patients will be diagnosed when transmural intestinal infarction has developed and at this time point damage control strategies involving intestinal revascularization, bowel resection, open abdomen and second look may be necessary to salvage the patient. This review outlines the principles of the damage control surgery approach in acute mesenteric ischemia and the rationale for temporary open abdomen. In patients in need of long-term open abdomen therapy, negative pressure wound therapy with continuous fascial traction is a preferred technique achieving a high delayed fascial closure rate.

Key words: open abdomen, acute mesenteric ischemia, superior mesenteric artery occlusion, peritonitis, intestinal revascularization, damage control laparotomy.

Anaesthesiol Intensive Ther 2019;51,2:159–162

Received: 25.02.2019, accepted: 19.05.2019

CORRESPONDING AUTHOR:

Prof. Stefan Acosta, Department of Clinical Sciences, Malmö, Lund University, Ruth Lundskaogsg 10, 205 02 Malmö, Sweden, e-mail: Stefan.acosta@med.lu.se

ADOPTING DAMAGE CONTROL SURGERY IN ACUTE MESENTERIC ISCHEMIA

The increasing use of revascularization of the mesenteric arterial circulation in acute mesenteric ischemia has created an increased demand for second or third look laparotomies for assessing bowel viability and definitive reconstructions of the bowel [1]. In patients who develop peritonitis, a damage control strategy is sensible [2]. The frequency of patients with acute mesenteric ischemia in series reporting damage control laparotomy in non-trauma patients varies between 13% [3] and 41% [4] (Table 1 [3–7]), which means that acute mesenteric ischemia is a common indication to leave the abdomen open. The survival rate was reported to be 62% in 16 actively treated patients in one series [2]. In a retrospective study of patients with peritonitis secondary to acute superior mesenteric artery (SMA) occlusion comparing open abdomen (OA) and primary fascial closure, non-OA patients more often required bowel resection at second look. Moreover, patients with primary fascial closure had higher rates of intra-abdominal sepsis, intra-abdominal hypertension, acute renal failure, short-bowel syndrome and mortality compared to OA patients [8].

In the recently developed “European Society of Vascular Surgery Guidelines on the management of diseases of the mesenteric arteries and veins”, damage control surgery and second look laparot-

omy are recommended when bowel infarction has developed in patients undergoing intestinal revascularization [9]. This strategy is less well studied in non-occlusive mesenteric ischemia and mesenteric venous gangrene [10], but liberal use of second look laparotomy seems to be a rational approach in these entities of acute mesenteric ischemia as well.

TREATMENT OF ACUTE SUPERIOR MESENTERIC ARTERY OCCLUSION

Optimal treatment may include both open and endovascular surgery, and patients are best treated in a vascular centre with a hybrid operating room, if available within a reasonable distance [11]. Evaluation of preoperative clinical status and computed tomography (CT) angiography are often enough to determine whether the patient has peritonitis or not, and whether the occlusion is embolic or

TABLE 1. Frequency of acute mesenteric ischemia in series of damage control laparotomy for non-trauma patients

First author (year)	Country	Acute mesenteric ischemia (%)
Person (2009) [5]	Israel	10/31 (31)
Subramanian (2010) [3]	USA	13/88 (13)
Goussous (2013) [6]	USA	25/111 (23)
Khan (2013) [7]	New Zealand	13/42 (31)
Girard (2017) [4]	France	68/164 (41)

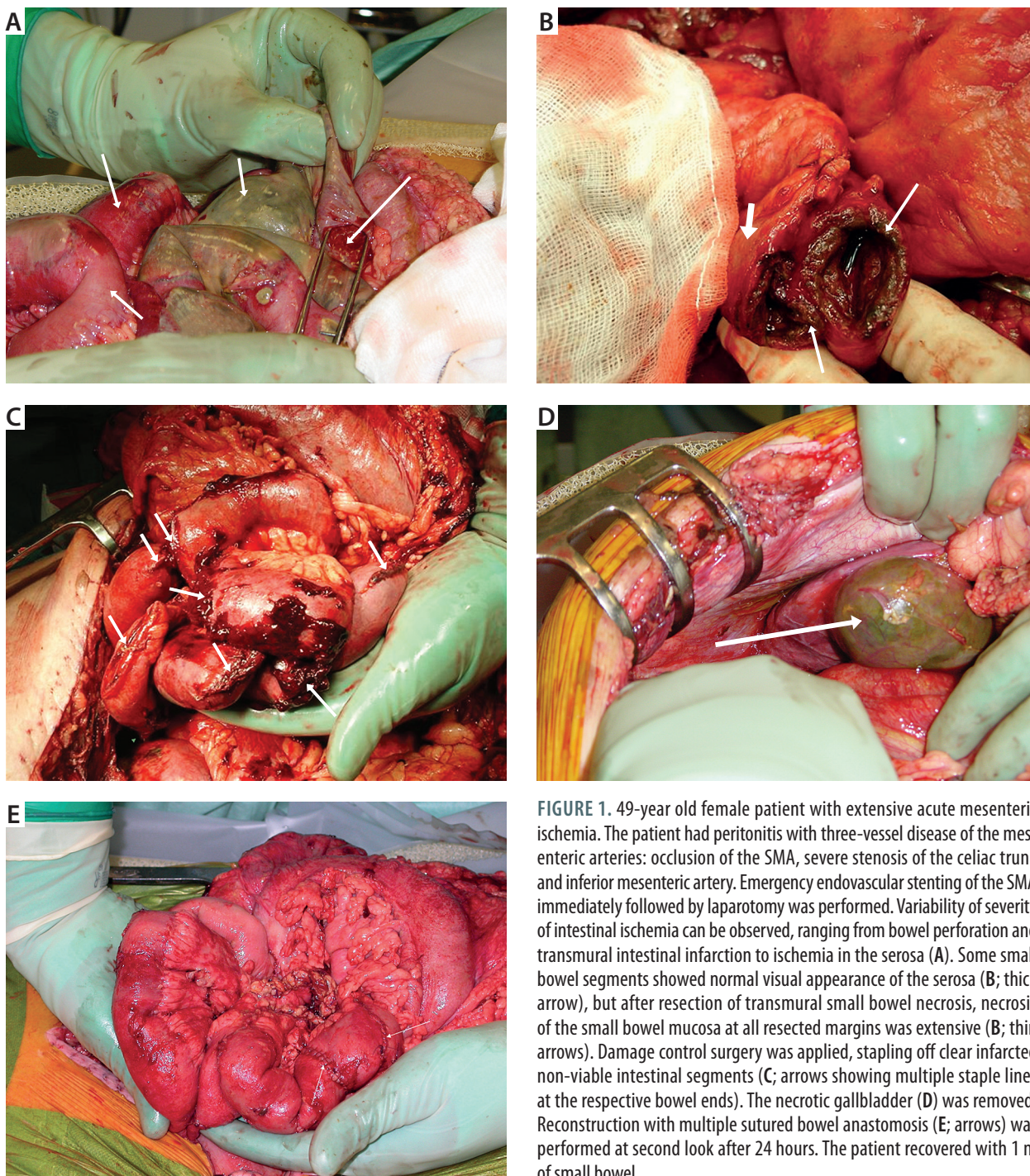


FIGURE 1. 49-year old female patient with extensive acute mesenteric ischemia. The patient had peritonitis with three-vessel disease of the mesenteric arteries: occlusion of the SMA, severe stenosis of the celiac trunk and inferior mesenteric artery. Emergency endovascular stenting of the SMA immediately followed by laparotomy was performed. Variability of severity of intestinal ischemia can be observed, ranging from bowel perforation and transmural intestinal infarction to ischemia in the serosa (A). Some small bowel segments showed normal visual appearance of the serosa (B; thick arrow), but after resection of transmural small bowel necrosis, necrosis of the small bowel mucosa at all resected margins was extensive (B; thin arrows). Damage control surgery was applied, stapling off clear infarcted non-viable intestinal segments (C; arrows showing multiple staple lines at the respective bowel ends). The necrotic gallbladder (D) was removed. Reconstruction with multiple sutured bowel anastomosis (E; arrows) was performed at second look after 24 hours. The patient recovered with 1 m of small bowel

thrombotic [12]. In the case of peritonitis, laparotomy is indicated to evaluate the extent and severity of intestinal ischemia by inspection of color of the intestines, dilatation and peristaltic motion of the bowel, palpable pulsations in the mesenteric arcade arteries, and bleeding from cut surfaces. Arterial revascularization, open, hybrid or endovascular, is done preferably before any bowel surgery [9]. There is rarely any indication for revascularization of both the SMA and the celiac trunk; SMA revascularization seems to be more important and durable.

In an acute thrombotic occlusion, retrograde open mesenteric stenting [13] may be a very useful hybrid approach where the SMA is exposed at laparotomy followed by retrograde recanalization of the thrombotic and atherosclerotic occlusion of the SMA and stenting in retrograde or antegrade manner. All initial emergency vascular procedures and all necessary damage control visceral surgery (Figure 1) should be performed during the same operation. Close collaboration between vascular and gastrointestinal surgeons is necessary to improve outcomes.

TEMPORARY ABDOMINAL CLOSURE IN ACUTE MESENTERIC ISCHEMIA

It should be remembered that intestinal ischemia may be extensive even if it is not evident by inspection during laparotomy, since ischemia starts from the mucosa side, propagating towards the serosa side later (Figures 1A and B). Even a low grade of intra-abdominal hypertension may become fatal when a large portion of the intestinal tract is ischemic [14]. In this situation it is important to optimize the perfusion of the remaining bowel, which often requires open abdomen treatment [1]. In the event of ischemic bowel perforation at laparotomy, the affected intestinal segment is rapidly resected, followed by mesenteric revascularization, leaving the reconstruction of the intestinal tract until second look laparotomy after 18-36 hours. The optimal temporary abdominal closure (TAC) method in patients with acute mesenteric ischemia is not clear. While temporary skin only closure may be a sufficient option in some patients, full open abdomen to optimize visceral circulation may be necessary in others.

OPEN ABDOMEN THERAPY WITH NEGATIVE PRESSURE WOUND THERAPY ON ISCHEMIC BOWEL

Negative pressure wound therapy (NPWT) has become standard therapy in patients with OA for the management of abdominal vascular emergencies [15]. There is, however, an ongoing discussion among surgeons whether the use of NPWT during OA may cause bowel damage, enteric leak and entero-atmospheric fistula [16–18]. Intuitively, patients with ischemic bowel should be considered to be at a greater risk of bowel injury during NPWT than patients with non-ischemic bowel. In case series without a control group, intestinal ischemia requiring bowel resection with anastomosis [19] and long-term NPWT in open abdomen due to secondary peritonitis [20] were factors reported to be associated with the development of entero-atmospheric fistulae and high mortality. It should be very clear, though, that OA therapy in itself, inevitably carries an inherent risk of bowel injury and intestinal fistula formation, with the bowel exposed to an unnatural environment and manipulated during dressing changes. Clinical data do not support a causal relationship between NPWT and intestinal fistula development [21–25]. In addition, an experimental study has shown that the actual negative pressure reaching the surface of the bowel during NPWT is only a few mm Hg, and it seems unlikely that this would cause pressure damage to the bowel wall [26]. However, a similar experimental setup in the presence of various degrees of small bowel ischemia is warranted to clarify whether NPWT has the potential to cause clinical and/or histological bowel injury.

In two recent systematic reviews with meta-analyses [27, 28] on OA and TAC techniques, NPWT with continuous fascial traction was associated with a higher delayed fascial closure rate and lower entero-atmospheric fistula formation rate compared to NPWT alone. This emphasizes the importance of having an effective method to close the abdomen as quickly as possible to reduce the risk of complications associated with OA therapy.

DELAYED BOWEL ANASTOMOSIS OR STOMA

Intestinal recovery may appear to occur very quickly after revascularization, but the surgeon can only inspect the intestines from the serosa side. Healing of any bowel anastomosis is considered to be better when the bowel anastomosis is performed delayed at second look compared to immediately at first explorative laparotomy. At the first or second look, bowel resection is performed quickly with staplers without reconstruction (Figure 1C). At the following laparotomy, bowel anastomosis or stoma is created. In one center, the practice was to routinely create a temporary stoma followed by administration of parenteral nutrition until the surgical recovery phase was over [29]. In patients undergoing extensive bowel resections, proximal resection of the jejunum, or multiple resections, bowel anastomosis after effective intestinal revascularization (Figure 1E) may be beneficial in avoiding high output stoma, short bowel syndrome and increased mortality associated with intestinal failure [30].

ACKNOWLEDGEMENTS

1. Financial support and sponsorship: none.
2. Conflict of interest: none.

REFERENCES

1. Acosta S, Björck M. Modern treatment of acute mesenteric ischemia. *Br J Surg* 2014; 101: e100-e108. doi: 10.1002/bjs.9330.
2. Freeman A, Graham J. Damage control surgery and angiography in cases of acute mesenteric ischaemia. *ANZ J Surg* 2005; 75: 308-314. doi: 10.1111/j.1445-2197.2005.03373.x.
3. Subramanian A, Balentine C, Palacio C, Sangsiry S, Berger D, Awad S. Outcomes of damage-control celiotomy in elderly non-trauma patients with intra-abdominal catastrophes. *Am J Surg* 2010; 200: 783-789. doi: 10.1016/j.amjsurg.2010.07.027.
4. Girard E, Abba J, Boussat B, et al. Damage control surgery for non-traumatic abdominal emergencies. *World J Surg* 2018; 42: 965-973. doi: 10.1007/s00268-017-4262-6.
5. Person B, Dorfman T, Bahouth H, Osman A, Assalia A, Kruger Y. Abbreviated emergency laparotomy in the non-trauma setting. *World J Emerg Surg* 2009; 4: 41. doi:10.1186/1749-7922-4-41.
6. Goussous N, Jenkins D, Zielinski M. Primary fascial closure after damage control laparotomy: sepsis vs haemorrhage. *Injury* 2014; 45: 151-155. doi: <https://doi.org/10.1016/j.injury.2013.01.039>.
7. Khan A, Hsee L, Mathur S, Civil I. Damage-control laparotomy in non-trauma patients: Review of indications and outcomes. *J Trauma Acute Care Surg* 2013; 75: 1-4. doi: 10.1097/TA.0b013e31829cb65e.
8. Ding W, Wang K, Liu B, et al. Open abdomen improves survival in patients with peritonitis secondary to acute superior mesenteric artery occlusion. *J Clin Gastroenterol* 2017; 51: e77-e82. doi: 10.1097/MCG.0000000000000799.

9. Björck M, Koelemay M, Acosta S, et al. European Society of Vascular Surgery Guidelines on the management of diseases of the mesenteric arteries and veins. Chapter 2: Mesenteric arterial ischaemia, acute occlusion. *Eur J Vasc Endovasc Surg* 2017; 53: 460-510.
10. Liu K, Meng J, Yang S, et al. Transcatheter thrombolysis combined with damage control surgery for treatment of acute mesenteric venous thrombosis associated with bowel necrosis: a retrospective study. *World J Emerg Surg* 2015; 10: 50. doi: 10.1186/s13017-015-0045-2.
11. Kärkkäinen JM, Acosta S. Acute mesenteric ischemia (Part II) – Vascular and endovascular surgical approaches. *Best Pract Res Clin Gastroenterol* 2017; 31: 27-38. doi: 10.1016/j.bpg.2016.11.003.
12. Kärkkäinen JM, Acosta S. Acute mesenteric ischemia (Part I) – Incidence, etiologies, and how to improve early diagnosis. *Best Pract Res Clin Gastroenterol* 2017; 31: 15-25. doi: 10.1016/j.bpg.2016.10.018.
13. Wyers MC, Powell RJ, Nolan BW, Cronenwett JL. Retrograde mesenteric stenting during laparotomy for acute occlusive mesenteric ischemia. *J Vasc Surg* 2007; 45: 269-275. doi: 10.1016/j.jvs.2006.10.047.
14. Björck M, Wanhainen A. Management of abdominal compartment syndrome and the open abdomen. *Eur J Vasc Endovasc Surg* 2014; 47: 279-287. doi: <https://doi.org/10.1016/j.ejvs.2013.12.014>.
15. Acosta S, Björck M, Petersson U. Vacuum-assisted wound closure and mesh-mediated fascial traction for open abdomen – a systematic review. *Anaesthesiol Intensive Ther* 2017; 49: 139-145. doi: 10.5603/AIT.a2017.0023.
16. Rao M, Burke D, Finan PJ, Sagar PM. The use of vacuum-assisted closure of abdominal wounds: a word of caution. *Colorectal Dis* 2007; 9: 266-268. doi: 10.1111/j.1463-1318.2006.01154.x.
17. Trevelyan SL, Carlson GL. Is TNP in the open abdomen safe and effective. *J Wound Care* 2009; 18: 24-25. doi: 10.12968/jowc.2009.18.1.32139.
18. Bee TK, Croce MA, Magnotti LJ, et al. Temporary abdominal closure techniques: a prospective randomized trial comparing polyglactin 910 mesh and vacuum-assisted closure. *J Trauma* 2008; 65: 337-342. doi: 10.1097/TA.0b013e31817fa451.
19. Acosta S, Bjarnason T, Pettersson U, et al. Multicentre prospective study of fascial closure rate after open abdomen with vacuum and mesh-mediated fascial traction. *Br J Surg* 2011; 98: 735-743. doi: 10.1002/bjs.7383.
20. Mintziras I, Miligkos M, Bartsch DK. High risk of fistula formation in vacuum-assisted closure therapy in patients with open abdomen due to secondary peritonitis – a retrospective analysis. *Langenbeck's Arch Surg* 2016; 401: 619-625. doi: 10.1007/s00423-016-1443-y.
21. Cheatham ML, Demetriades D, Fabian TC, et al. Prospective study examining clinical outcomes associated with a negative pressure wound therapy system and Barker's vacuum packing technique. *World J Surg* 2013; 37: 2018-2030. doi: 10.1007/s00268-013-2080-z.
22. Carlson GL, Patrick H, Amin AI, et al. Management of the open abdomen: a national study of clinical outcome and safety of negative pressure wound therapy. *Ann Surg* 2013; 257: 1154-1159. doi: 10.1097/SLA.0b013e31828b8bc8.
23. Montori G, Allevi N, Coccolini F, et al. Negative pressure wound therapy versus Barker Vacuum Pack as temporary abdominal closure technique for open abdomen management: a four-year experience. *BMC Surg* 2017; 17: 86. doi: 10.1186/s12893-017-0281-3.
24. Marinis A, Gkiokas G, Argyra E, Fragulidis G, Polymeneas G, Voros D. "Enteroatmospheric fistulae" – gastrointestinal openings in the open abdomen: a review and recent proposal of a surgical technique. *Scand J Surg* 2013; 102: 61-68. doi: <https://doi.org/10.1177/1457496913482252>.
25. Becker HP, Willms A, Schwab R. Small bowel fistulas and the open abdomen. *Scand J Surg* 2007; 96: 263-271. doi: 10.1177/145749690709600402.
26. Bjarnason T, Montgomery A, Hlebowicz J, Lindstedt S, Petersson U. Pressure at the bowel surface during topical negative pressure therapy of the open abdomen: an experimental study in a porcine model. *World J Surg* 2011; 35: 917-923. doi: 10.1007/s00268-010-0937-y.
27. Atema JJ, Gans SL, Boermester MA. Systematic review and meta-analysis of the open abdomen and temporary abdominal closure techniques in non-trauma patients. *World J Surg* 2015; 39: 912-925. doi: 10.1007/s00268-014-2883-6.
28. Cristaudo A, Jennings S, Gunnarsson R, DeCosta A. Complications and mortality associated with temporary abdominal closure techniques: A systematic review and meta-analysis. *Am Surg* 2017; 83: 191-216.
29. Roussel A, Castier Y, Nuzzo O, et al. Revascularization of acute mesenteric ischemia after creation of a dedicated multidisciplinary center. *J Vasc Surg* 2015; 62: 1251-1256. doi: 10.1016/j.jvs.2015.06.204.
30. Block TA, Acosta S, Björck M. Endovascular and open surgery for acute occlusion of the superior mesenteric artery. *J Vasc Surg* 2010; 52: 959-966. doi: 10.1016/j.jvs.2010.05.084.