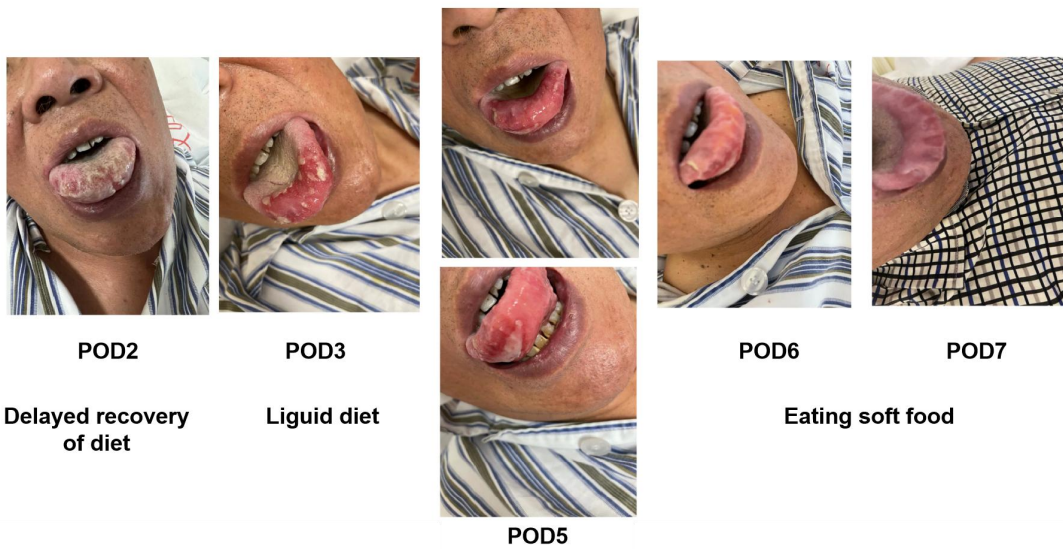


Tongue swelling and dysphagia occurred after posterior lumbar surgery



Clinical Manifestations of POPLD

A 65-year-old male underwent a 6-h elective posterior spinal surgery on a radiolucent operating table with the head placed on a horseshoe-shaped head ring. Before and during the surgery, no abnormal surgical position or remarkable events were observed. After tracheal extubation, the patient complained of tongue numbness and experienced dysphagia. The oral diet and water intake recovery was delayed, and intravenous fluid therapy was administered. Progressive swelling of the tongue was visible; there were no respiratory symptoms. Following glucocorticoid treatment, the symptoms were relieved within 1 week and the patient was discharged from the hospital. The patient complained of dissatisfaction with the treatment.